

Takotsubo cardiomyopathy in early term pregnancy: a rare cardiac complication of SARS-CoV-2 infection

Pranab J Bhattacharyya, Pawan K Attri, Waseem Farooqui

Department of Cardiology,
Gauhati Medical College and
Hospital, Guwahati, India

Correspondence to
Professor Pranab J
Bhattacharyya;
drpranabguwahati@gmail.com

Accepted 20 September 2020

DESCRIPTION

A 32-year-old primigravida at a 38-week gestation was initially admitted in cardiology isolation ward on referral by her local obstetrician for inferolateral ST-segment elevation on ECG (figure 1A) which was obtained for complaints of New York Heart Association functional class II symptoms with palpitations of a 3-day duration. Except for a blood pressure of 150/100 mm Hg on presentation, the rest of her physical examination, vital signs and medical history were insignificant. She was on amlodipine for gestational hypertension. A transthoracic echocardiogram (TTE) demonstrated hypokinetic mid and akinetic apical left ventricular (LV) segments and hypercontractile basal segments with prominent apical ballooning typical of takotsubo cardiomyopathy (TTC) (figure 1B, arrows). Two-dimensional speckle tracking echocardiography revealed LV global longitudinal strain (GLS) of -13.9 and ejection fraction (EF%) of 38% (figure 1C). Blood tests showed elevated troponin I (37.00 pg/mL, normal <26.20) and N-terminal pro b-type natriuretic peptide (NT-proBNP) (1312.00 pg/mL, normal <115.00). Nasopharyngeal swab reverse transcription PCR (RT-PCR) test was positive for SARS-CoV-2 infection. Coronary angiography (CAG) was deferred due to her active COVID-19 status. She was further managed in the ward of our dedicated COVID-19 hospital where she was started on medical therapy with bisoprolol and enoxaparin (40 mg subcutaneous two times per day for 5 days) along with oral vitamins and antibiotic as per local treatment protocol for patients with COVID-19. Regular maternal and fetal monitoring continued. As oxygen saturation in room air and respiratory rate were maintained within normal limits without any clinical evidence of pneumonia or respiratory failure, she did not require management in the intensive care unit for either non-invasive or invasive mechanical ventilation at any stage during her 7-day stay in the COVID-19 ward. Additional laboratory tests showed leucocytosis ($20.48 \times 10^9/\mu\text{L}$, normal 4.00–11.00), neutrophilia (85.8%, normal range 37–72), lymphopenia (9.2%, normal range 20–40), neutrophil-lymphocyte ratio (9, normal 1–3), raised levels of D-dimer (0.69 $\mu\text{g/mL}$, normal <0.05), lactate dehydrogenase (456 U/L, normal range 120–246), alkaline phosphatase (188 U/L, normal range 38–126) and globulin (3.5 g/dL, normal range 2.80–3.20), low levels of albumin (3.0 g/dL, normal range 3.50–5.00) and albumin/globulin ratio (0.90, normal 1.25–1.51) and normal levels of ferritin (116 ng/mL, normal range 11–306.8), total

bilirubin (0.50 mg/dL, normal range 0.20–1.3), aspartate aminotransferase (37 U/L, normal 17–59) and alanine aminotransferase (28 U/L, normal range 4–50). On day 8, her RT-PCR test was negative and due to the onset of early labour, she was shifted to labour and delivery ward for necessary obstetrical management. Subsequently on the same day, she underwent an uneventful caesarean section delivery under spinal anaesthesia for fetal distress and associated cephalopelvic disproportion. Despite a diagnosis of TTC, an expedited delivery in our patient was not considered by the obstetrical unit as there was no evidence of clinical or haemodynamic worsening of maternal or fetal status. Repeat TTE on day 13 on transfer to the cardiology ward showed the normalisation of the LV regional wall motion abnormalities (RWMA) and significant improvement of GLS (-16.5) and EF% (51%) (figure 1D) further ratifying the diagnosis of TTC. Subsequent CAG on day 14 revealed non-obstructive coronary artery disease (CAD) involving the left anterior descending artery (figure 1E, arrows). She was finally discharged from the cardiology ward after full recovery on day 16 with aspirin, atorvastatin and bisoprolol.

As typified by this index case, TTC can mimic acute ST-segment elevation myocardial infarction and is considered to be a reversible form of cardiomyopathy characterised by a complete recovery of RWMA and LV function within weeks of presentation. Incidental CAD can be present in up to 10%

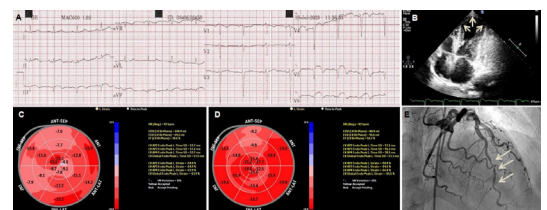


Figure 1 (A) Presenting ECG showing ST-segment elevation in inferolateral leads. (B) Apical ballooning on two dimensional transthoracic echocardiogram (arrows). (C) The 18-segment left ventricular Bull's eye plot on two dimensional speckle tracking echocardiography demonstrating left ventricular dysfunction (light red colour denoting reduced global longitudinal strain value and reduced ejection fraction). (D) Normalisation of echocardiographic abnormalities within 2 weeks of presentation (almost uniformly red pattern of bull's eye plot representing normal strain values and left ventricular ejection fraction). (E) Coronary angiography demonstrating non-obstructive coronary artery disease in left anterior descending artery (arrows).

Check for updates

© BMJ Publishing Group Limited 2020. No commercial re-use. See rights and permissions. Published by BMJ.

To cite: Bhattacharyya PJ, Attri PK, Farooqui W. *BMJ Case Rep* 2020;**13**:e239104. doi:10.1136/bcr-2020-239104

Images in...

cases.¹ Although TTC classically affects postmenopausal women, it has been infrequently reported previously in pregnant women unrelated to SARS-CoV-2 infection.² This is the first reported case of TTC in pregnancy as a manifestation of SARS-CoV-2 infection during this ongoing pandemic.

TTC can be preceded by emotional or physical stressful triggers. Coronary artery vasospasm, coronary microvascular dysfunction, LV outflow tract obstruction and catecholamine surge have all been elucidated as potential mechanisms. As TTC has also been reported with viral infections, the more intense inflammation associated with COVID-19 may contribute to

its development. Deranged inflammatory markers were also a notable finding in our patient described previously. Whether the inflammatory response of SARS-CoV-2 infection and any specific markers that may portend a greater likelihood of development of TTC especially in pregnancy may be a subject matter for further study. The overall prognosis of TTC is favourable, with full recovery of LV function seen in most patients by 2 months.³ Pregnant women may be at greater risk for SARS-CoV-2 infection as the virus enters the cell via the ACE 2 receptor, which is upregulated in normal pregnancy.⁴

Therefore, treating physicians dealing with the COVID-19-positive pregnant population need to remain vigilant towards this rare cardiac complication of SARS-CoV-2 infection.

Patient's perspective

I express my gratitude to the entire team of doctors and healthcare workers for providing me best possible care leading to my complete recovery.

Learning points

- ▶ The presentation of takotsubo cardiomyopathy can mimic ST-segment elevation myocardial infarction but in the absence of angiographic evidence of significant obstructive coronary artery disease.
- ▶ Typical echocardiographic finding is reversible left ventricular apical ballooning (resembling the 'takotsubo' or Japanese 'octopus trap') with systolic dysfunction.
- ▶ This condition can be triggered by high emotional stress with a preponderance in postmenopausal women.
- ▶ For the first time during this ongoing pandemic, this entity has been documented to occur as a cardiac complication of SARS-CoV-2 infection in term pregnancy.
- ▶ Appropriate conservative management leads to its complete recovery.

Contributors PJB, PKA, and WF were involved in patient management. PJB prepared the manuscript. PJB and PKA acquired the echocardiographic images and PJB and WF performed the coronary angiogram. All authors have revised the manuscript and approved of the final draft.

Funding The authors have not declared a specific grant for this research from any funding agency in the public, commercial or not-for-profit sectors.

Competing interests None declared.

Patient consent for publication Obtained.

Provenance and peer review Not commissioned; externally peer reviewed.

This article is made freely available for use in accordance with BMJ's website terms and conditions for the duration of the covid-19 pandemic or until otherwise determined by BMJ. You may use, download and print the article for any lawful, non-commercial purpose (including text and data mining) provided that all copyright notices and trade marks are retained.

REFERENCES

- 1 Patel MR, Singh M, Gersh BJ, *et al*. Chapter 40 ST-Segment Elevation Myocardial Infarction. In: Fuster V, Harrington RA, Narula J, *et al*, eds. *Hurst's the Heart, Fourteenth Edition*. New York: McGraw-Hill Education, 2017: 1017–54.
- 2 Brezina P, Isler CM. Takotsubo cardiomyopathy in pregnancy. *Obstet Gynecol* 2008;112:450–2.
- 3 Minhas AS, Scheel P, Garibaldi B, *et al*. Takotsubo syndrome in the setting of COVID-19. *JACC Case Rep* 2020;2:1321–5.
- 4 Narang K, Enninga EAL, Gunaratne MDSK, *et al*. SARS-CoV-2 infection and COVID-19 during pregnancy: a multidisciplinary review. *Mayo Clin Proc* 2020;95:1750–65.

Copyright 2020 BMJ Publishing Group. All rights reserved. For permission to reuse any of this content visit <https://www.bmj.com/company/products-services/rights-and-licensing/permissions/>
BMJ Case Report Fellows may re-use this article for personal use and teaching without any further permission.

Become a Fellow of BMJ Case Reports today and you can:

- ▶ Submit as many cases as you like
- ▶ Enjoy fast sympathetic peer review and rapid publication of accepted articles
- ▶ Access all the published articles
- ▶ Re-use any of the published material for personal use and teaching without further permission

Customer Service

If you have any further queries about your subscription, please contact our customer services team on +44 (0) 207111 1105 or via email at support@bmj.com.

Visit casereports.bmj.com for more articles like this and to become a Fellow